

Histological and Scanning Electron Microscopy Assessment of Various Vital Pulp-Therapy Materials

Mercedes S. Dominguez, David E. Witherspoon, James L. Gutmann, and Lynne A. Opperman

Pulp capping and pulpotomy procedures were performed on 15 male mongrel dogs. Three materials were used: calcium hydroxide, acid-etched dentin bonding, and mineral trioxide aggregate. Six of the animals were killed at 50 days and nine were killed at 150 days. Samples from 11 dogs were used for histological evaluation, and the remaining dog samples were used for scanning electron microscopy evaluation. Each slide was graded histologically according to previously published criteria. Scanning electron microscopy analysis was performed, and the weight percentage of elements found in the dentin of a nontreated tooth versus the bridge formed in the exposed specimen was established. By evaluating pulp inflammation in vital pulp-therapy treatments, it was found that mineral trioxide aggregate was not significantly different from the untreated control group, both in pulp-capping procedures at 50 days ($p = 0.357$) or 150 days ($p = 0.198$) and pulpotomy procedures at 50 days ($p = 0.357$) or 150 days ($p = 0.198$). Moreover, histologically mineral trioxide aggregate was a considerably better material than calcium hydroxide or acid-etched dentin bonding in maintaining the integrity of the pulp.

In pulp-capping and pulpotomy techniques a biocompatible or bio-inductive material is placed over the exposed tissue. Pulp capping is defined as the placement of a dental material over an exposed, or nearly exposed, pulp to initiate the formation of irritation dentin at the site of injury. Pulpotomy, on the other hand, is the surgical removal of a small portion of the vital, coronal pulp as a means of preserving the vitality of the remaining radicular pulp tissue.

Historically, various materials have been used in pulp-capping and pulpotomy procedures. These include, but are not limited to: ivory, quill, gold-beaters skin, oiled skin, paper, plaster of Paris, Canada Balsam, asbestos, gutta-percha, lactophosphate of lime, oxychloride, oxyphosphate, and oxyulphate of zinc cement. In the past, astringent of tannin in glycerin and tincture of nutgalls were

also applied to the exposed pulp before placing the capping material (1).

Classically, different formulations of calcium hydroxide (CH) have been used. Today, newer materials are being advocated for vital pulp therapy, with mineral trioxide aggregate (MTA) and different formulations of dentin-bonding materials being most recently promoted. Although thousands of pulp-capping and pulpotomy procedures are performed in the United States alone every year, the response of the pulp tissue to different materials, such as CH, acid-etch composites, and MTA, has only been evaluated individually on a histological basis. Furthermore, the chemical makeup of the hard-tissue barrier formed in response to the vital pulp-therapy materials has not been elucidated. It is unknown if this barrier has the same element composition as sound dentin; additionally, the element weight percentage in the formed barrier could vary depending on the material used for the different vital pulp-therapy treatments.

CH has been the material of choice for pulp capping and pulpotomies because (a) it seems to stimulate a rapid differentiation of odontoblasts or odontoblast-like cells that form a hard-tissue barrier in the pulp (2); and (b) it is antibacterial (3). There are no studies that indicate that this material uniquely stimulates hard-tissue formation at rates faster than any other material, nor has the exact mechanism by which CH generates a dentin bridge been elucidated (4). However, the pulpal response to CH has been described histologically (4, 5).

The use of acid-etched, dentin-bonded materials (AEDB) for pulp capping and pulpotomy is controversial, being both advocated (6) and contraindicated (7). The basis for their advocacy lies in the fact that AEDB can establish a bacterial, leak-proof environment. However, their exact mechanisms of action on the pulp are not known, although they have been described histologically (8).

A newer material that is advocated for vital pulp therapy, MTA, is composed of calcium silicate (CaSiO_4), bismuth oxide (Bi_2O_3), calcium carbonate (CaCO_3), calcium sulfate (CaSO_4), and calcium aluminate (CaAl_2O_4). When mixed with water, MTA forms crystals of calcium oxide in an amorphous structure consisting of 33% calcium, 49% phosphate, 2% carbon, 3% chloride, and 6% silica (9). Developed primarily for use as a root-end filling (10), it stimulates significantly greater hard-tissue formation in the periradicular tissues and results in less inflammation compared with the use of calcium hydroxide (11). In another study, the pulps of 12 mandibular incisors in monkeys were exposed and capped with MTA or a CH preparation. After 5 months the animals were killed and the specimens examined histologically; the study concluded

that there was no inflammation in five of six samples capped with MTA, and these specimens also had formation of a complete dentinal bridge. In contrast, all the pulps capped with CH showed pulpal inflammation, with hard-tissue bridge formed in only two of the samples (12).

Although many studies can be found regarding CH, AEDB, and MTA as separate entities, these three contemporary materials have not been characterized histologically together in an *in vivo* study, nor has the nature of the hard-tissue barrier that forms been characterized on more than a histological level.

The objectives of this study were: (a) to characterize and compare histologically the response of the pulp in pulp-capping and pulpotomy procedures using CH, AEDB, and MTA at 50 and 150 days; and (b) to characterize the nature of the specific elements found in the hard-tissue barrier formed adjacent to each of the pulp-therapy materials.

MATERIALS AND METHODS

Animal Model

Fifteen male mongrel dogs, each approximately 50 lb and older than 18 months of age, were obtained and quarantined from 7 to 10 days to ensure optimal health before the study. The animals were housed in Baylor College of Dentistry's Animal Research Unit, and their care followed guidelines established by the Institutional Animal Care and Use Committee (IACUC). All animals were monitored daily before the treatment phase. The animals were killed randomly at two time intervals. Six dogs were killed at 50 days, and nine were killed at 150 days. For all phases of the treatment, general anesthesia of the animals was obtained by intramuscular injection of 1 to 2.2 mg/kg of Rompun and 20 mg/kg of Ketamine. Intraoral anesthesia in the mandibular teeth was achieved by anesthetic block injection of 1.8 ml of 2% lidocaine containing 1:100,000 epinephrine, and in the maxilla by infiltration injection of 1.8 ml of 2% lidocaine containing 1:100,000 epinephrine. The use of local anesthesia in conjunction with general anesthesia follows the established protocol for all animal studies at Baylor College of Dentistry. All products used in the experimental phase are detailed in Table 1.

Pulp Capping

The central and lateral incisors from the maxilla of each animal were allocated randomly to the pulp-capping treatment groups listed below. Initially, a pinpoint pulpal exposure was made in all teeth using high-speed diamond burs (855, H21; Brasseler USA, Savannah, GA, U.S.A.) using copious water spray. The exposure was then rinsed with sterile saline until the hemorrhage stopped. Subsequent treatment was performed as follows:

1. Light-cure Ca(OH)₂ was placed over the exposure and light-cured for 20 s. The remainder of the cavity preparation was restored with Ketac Silver (3M ESPE, St. Paul, MN).
2. Exposures were acid-etched with Ultra-Etch (35% phosphoric acid) (Ultradent Products, Inc., South Jordan, UT) for 15 s, washed with water for 5 s, then air-dried but not desiccated. PQ1 one-step dentin-bonding agent (Bisco Dental Products, Itasca, IL) was applied in a thin layer and light-cured for 20 s over the exposures. The remainder of the cavity was restored with Amelogen Universal (Ultradent). Because dentin bonding has restorative properties that MTA and CH do not share, its presence does not necessitate the use of Ketac Silver. For this reason, Amelogen Universal (Ultradent Products, Inc., South Jordan, UT, U.S.A.) was used in all dentin bonding-treated teeth.
3. MTA was mixed according to the manufacturer's recommendations and placed over the exposure. Excess water was removed and the remainder of the cavity preparation was restored with Ketac Silver.

Pulpotomy

The maxillary third and fourth premolar from each animal were allocated randomly to one of the treatment groups listed below. Initially, the coronal pulp was removed to the level of the CEJ in each root canal system using high-speed diamond burs (855, H21; Brasseler USA) using copious water spray. The exposure was then rinsed with sterile saline until the hemorrhage stopped. Subsequent treatment was performed as follows.

1. Light-cure Ca(OH)₂ was placed over the pulp stump layer and light-cured for 20 s. The remainder of the cavity was restored with Ketac Silver.
2. The dental pulp stump was acid-etched with Ultra-Etch for 15 s, washed with water for 5 s, and then air-dried but not desiccated. PQ1 one-step dentin-bonding agent was applied in a thin layer and light-cured for 20 s. The remainder of the cavity was restored with Amelogen Universal.
3. MTA was mixed according to the manufacturer's recommendations and placed over the pulp stump. Excess water was removed with small cotton pellets, and the remainder of the cavity preparation was restored with Ketac Silver.

Control Specimens

The controls were selected from among untreated, intact lateral and central incisors on which no pulp capping or pulpotomy was performed. Eight incisors were chosen: four from the 50-day group and another four from the 150-day group.

TABLE 1. Products used

Product	Trade Name	Company	Location	Formulation
CH	Ultra-Blend <i>plus</i>	Ultradent	South Jordan, UT	Light-cured
MTA	ProRoot	Dentsply	Tulsa, OK	Gray/production
35% Phosphoric acid	Ultra-Etch	Ultradent	South Jordan, UT	Injectable
Glass ionomer	Ketac Silver	ESPE	St. Paul, MN	Capsule
Dentin-bonding agent	PQ1	Ultradent	South Jordan, UT	Syringe
Composite	Amelogen Universal	Ultradent	South Jordan, UT	Syringe

TABLE 2. Pulpal inflammation

Scoring	Description
1	No inflammation
2	Minimal inflammation
3	Moderate inflammation
4	Severe inflammation
5	Abscess formation
6	Tissue necrosis

Tissue Removal and Processing

Animals were killed at the designated time period. Before sacrifice, the animals were anesthetized with intravenous administration of sodium pentobarbital 33 mg/kg. The right and left common carotid arteries and external jugular veins were exposed surgically and the common carotid arteries were cannulated with a positive pressure-perfusion system. Approximately 20 ml of 20% potassium chloride solution were injected into the external jugular vein to fibrillate the heart. After the overdose and the lack of palpable pulse, the carotid artery was perfused with 1.0 to 1.5 L of saline, followed by 1.0 to 1.5 L of 10% phosphate-buffered formalin at a pressure of 120 to 140 mm Hg, for internal fixation of these tissues. Block sections of the mandible and maxilla were removed using a Stryker autopsy saw. All sections were placed into a 10% formalin solution for further tissue fixation.

Tissue Processing

Specimens for demineralization were placed in 0.5 M EDTA at 4°C for 3 to 6 months. To enhance the rate of demineralization, the blocks were sectioned into smaller segments containing one tooth. Demineralization was complete when the section demonstrated an absence of radiopaque structures upon radiographic evaluation at 60 kVp, 15 mA, 18 impulse (General Electric, model 46-158800G2, Louisville, KY, U.S.A.). The block specimens were dehydrated in alcohol and infused with Paraplast Plus Paraffin using the Technicon. The block sections were embedded in paraffin wax and sectioned serially at 5.0 to 7.0 μ using a microtome. Sectioning began at the center of the root canal and progressed until evaluation material was no longer available from the section. Fifteen randomly selected, representative sections were used from the central portion of each root. Three sections were stained with hematoxylin and eosin (H & E).

Histological examination was performed by two examiners independently and via collective consultation on those specimens upon which agreement was not achieved initially. Then, a final grade was assigned to specimens. Before histological examination, each examiner underwent a training process with reference to the scoring system outlined below. Each section (slide) was graded according to criteria that were based on a modified scoring system adapted from Stanley (4), as indicated in Tables 2 to 9.

Scanning Electron Microscopy

One tooth from each long-term experimental group was randomly selected for scanning electron microscope (SEM) analysis. After fixation, the undemineralized specimens were embedded in methylmethacrylate, sectioned at 50 μ , polished and sputter-coated with 30 nm of a gold/palladium mixture for SEM (SEM-JEOL

TABLE 3. Tissue reaction to the material

Scoring	Description
0	No macrophages and/or multinucleated giant cells adjacent to material
1	Mild-to-moderate infiltration of macrophages and/or multinucleated giant cells
2	Moderate infiltration of macrophages and/or multinucleated giant cells
3	Severe infiltration of macrophages and/or multinucleated giant cells

TABLE 4. Impaction of particles of pulp-capping agents

Scoring	Description
1	No impaction of pulp-capping agents
2	Impaction of pulp-capping agents

TABLE 5. Location of dentin bridge

Scoring	Description
1	At the interface of exposure pulp
2	Not at the interface of exposure pulp
3	Combination

TABLE 6. Presence of dentin chips

Scoring	Description
0	No chips
1	Chipitis
2	Double dentin bridges
3	Pulp stones

TABLE 7. Dentin bridge formation

Scoring	Description
0	No presence of bridge formation
1	Bridge formation <25%
2	25% bridge formation <50%
3	50% bridge formation <75%
4	Bridge formation 75%

TABLE 8. Quality of dentin formation in the bridge

Scoring	Description
0	No tubules present
1	Irregular pattern of tubules
2	Regular pattern of tubules

JSM 6300; JEOL USA Inc., Peabody, MA, U.S.A.). Energy-dispersive X-ray analysis (EDXA) (Noran Voyager System; Middleton, WI, U.S.A.) was used to determine the chemical content of the samples processed for SEM evaluation. Three points were selected for analysis both in the dentin bridge and in the normal dentin of an untreated tooth.

SEM analysis was performed at a magnification of $\times 2000$ with a working distance of 25 units. Dead time was between 20 and 24%. The whole screen area was analyzed three times at different sites of the bridge area. The collected data were compared to the dentin of an untreated tooth. The means of the weight percentage of the elements found in the samples were then compared.

TABLE 9. Connective tissue in the bridge

Scoring	Description
0	No connective tissue
1	Connective tissue <25%
2	25% connective tissue <50%
3	50% connective tissue <75%
4	Connective tissue 75%

Statistical Analysis

For all relevant criteria scored, independent-sample, *t* test comparisons of means were performed initially to test whether significant differences existed between the two independent examiners' mean scores. Because no significant differences between the two examiners were found at the $\alpha = 0.05$ level, the examiners' scores were combined in each criterion and were substituted by their numeric mean. Subsequent statistical analysis was carried out only on these scores.

The only criterion for which sufficient observation points existed to perform statistical analysis was pulpal inflammation. The null hypothesis was that treated teeth have the same level of pulpal inflammation as untreated teeth at the two different periods. The following two sets of analyses were carried out regarding pulpal inflammation:

- Simultaneous comparison of the means of the three treatment groups and the control at the two different periods (50 and 150 days) via ANOVA. Contrasts were set to test specific relations among means. Post-hoc multiple comparisons also were run including: (a) the Bonferroni adjustment to significance levels for pairwise comparisons; and (b) Tukey's and Duncan's range tests for identification of homogenous group subsets.
- Two-sample inference via computation of Mann-Whitney (or Wilcoxon rank sum) nonparametric statistics. The three treatment groups were pairwise compared to the control at 50 and 150 days. Exact one-sided *p* values were computed and compared to the $p = 0.05$ level.

Because the data set was small, sparse, possibly contained ties, and the scores were not always normally distributed, the underlying assumptions necessary for reliable results via the standard *asymptotic* method were not applicable. Thus, in all mean-comparison tests, the SPSS Exact Tests (v.10.0.7; SPSS Inc, Chicago, IL, U.S.A.) module was used. This module allows the calculation of significance levels based on the *exact* distribution of the test statistic.

RESULTS

Histological Assessment

The following results are based on the scored criteria that were observed on the sections.

Pulp Capping: CH

1. 50% (5/10) of the cases had pulpal necrosis.
2. Only one case had no inflammation present, whereas one case in the long-term group had mild inflammation.
3. 29% (2/7) of the cases had impaction of the material in the pulp. One of these cases did not have necrosis; however, CH was impacted in the pulp. The other case was necrotic.

4. 20% (1/5) of the cases had dentin chips present.
5. One of the cases had complete bridge formation, although it also had abscess formation in the 50-day group. 60% (3/5) of the cases had partial bridge formation.
6. 50% (2/4) of the cases had connective tissue formation in the bridge.
7. Bridging was present half of the time at the exposure pulp interface.

Pulp Capping: AEDB

1. 50% (4/8) of the cases had pulpal necrosis, 12.5% (1/8) had abscess formation, and the remaining 37.5% (3/8) had minimal inflammation.
2. The cases that were not necrotic had minimal reaction to the material.
3. Only 20% (1/5) of the 50-day cases had impaction of the material; a necrotic pulp was also present.
4. Bridging did not occur at the pulp exposure interface. However, tubules were present in these bridge formations.
5. No dentin chips were found in the pulp.
6. Connective tissue was present in 67% (2/3) of the cases.

Pulp Capping: MTA

1. Only 10% (1/10) of the 150-day cases had pulpal necrosis. From the remaining 90% (9/10), half showed minimal pulpal inflammatory reactions.
2. 40% (2/5) of the cases had MTA impacted in the pulp.
3. 60% (3/5) of the cases had dentin chips in the pulp.
4. 33% (2/6) of the cases had complete bridge formation. In the total set of cases, half developed bridging at the pulp exposure interface and half had some type of tubule formation and connective tissue.

Pulpotomy: CH

1. 80% (8/10) of the cases had pulpal necrosis.
2. 30% (3/10) of the cases had no tissue reaction or presence of macrophages.
3. 50% (2/4) of the cases had complete bridge formation and the other half had partial bridge formation in the 50-day group. Tubule formation was observed in 75% (3/4) of the specimens, mostly irregular in nature. Location of the bridging was present at the pulp exposure interface in all cases.
4. 33% (2/6) of the cases had material impacted in the pulp, whereas dentin chips occurred in 80% (4/5).
5. 75% (3/4) of the cases had connective tissue formation in the bridge.

Pulpotomy: AEDB

1. 62.5% (5/8) of the cases had pulpal necrosis; the remaining 37.5% (3/8) had mild inflammation.
2. The cases that were not necrotic had minimal reaction to the material.
3. 29% (2/7) of the cases had material impaction. One of these cases was necrotic and the other had minimal inflammation.
4. Bridging occurred equally at the pulp exposure interface and other pulp locations.
5. 60% (3/5) of the cases had dentin chips in the pulp, with the majority of them being observed in the 150-day group.
6. 75% (3/4) of the cases had complete bridging, with the remaining showing only partial bridging. Tubules were

present in all of the dentin bridges, with half of the cases exhibiting a regular tubule pattern.

7. Connective tissue was present in 75% (3/4) of the bridges.

Pulpotomy: MTA

1. MTA caused minimal pulpal inflammation. Pulpal necrosis was observed in only 10% (1/10) of the 150-day cases.
2. 40% (2/5) of the cases had impaction of pulp capping agents.
3. All cases developed bridging at the pulp-exposure interface.
4. 60% (3/5) of the cases had dentin chip impaction.
5. 40% (2/5) of the visible cases showed complete bridge formation, whereas the remaining 60% had incomplete bridge formation. 60% of the bridges had tubules present.
6. 75% (3/4) of the cases had connective tissue in the bridge.

These histological assessment results are summarized in Tables 10 and 11.

Statistical Results

In pulp capping, the use of both CH and AEDB resulted in statistically significant differences from the control group in both time periods: at 50 days, $p_{CH} = 0.029$ and $p_{AEDB} = 0.048$; at 150 days, $p_{CH} = 0.015$ and $p_{AEDB} = 0.029$. Conversely, no significant differences between MTA and the control were observed in the short-term ($p_{MTA} = 0.119$) or in the long-term ($p_{MTA} = 0.057$).

In pulpotomy procedures, both CH and AEDB were not significantly different from the control at 50 days ($p_{CH} = 0.119$, $p_{AEDB} = 0.114$). However, at 150 days, teeth treated both with CH and AEDB showed significant differences ($p_{CH} = 0.014$, $p_{AEDB} = 0.40$). The use of MTA resulted in no significant differences either in the short-term ($p_{MTA} = 0.357$) or in the long-term ($p_{MTA} = 0.198$).

The means and standard deviations from the statistical assessment are described in Table 12.

Pulp Capping: SEM

The bridges from the pulp-capping procedures were measured with SEM dispersive X-ray analysis and were compared with a tooth that had no treatment. The findings were classified by the components' element characteristics and are purely descriptive; that is, no statistical-significance testing of differences could be applied. The results are reported in Figs. 1 and 2 and are summarized below:

- **Organic components:** AEDB resulted in higher mean concentrations of carbon than the control compared with CH and MTA, with the CH treatment group being closest to the control. MTA's mean weight percentages of both oxygen and sodium were closest to the control's concentrations.
- **Mineral components:** In general, the calcified component (magnesium, calcium, and phosphate) of the bridge was higher for CH and MTA than for AEDB.

Pulpotomy: SEM

Bridge formation in pulpotomies was similarly analyzed. The results are reported in Figs. 3 and 4 and are summarized below:

TABLE 10. Pulp capping

Material	Time (Days)	Inflammation (%)		Impactation of Pulp-capping Agents (%)	Dentin Bridge Formation (%)		Dentin Chips (%)	Dentin Formation Quality (Tubules) (%)		Dentin Bridge Location (%)		Connective Tissue (%)	
		Slight or No Inflammation	Necrosis		Complete	Incomplete		Present	Absent	Pulp Exposure Interface	Other Locations	Present	Absent
MTA	150	30	10	15	40	15	15	30	15	35	40	20	
	50	60	16	15	30	15	15	30	15	15	20	20	
AEDB	150	24	50	100	20	10	25	90	10	50	50	25	
	50	12	38	20	60	20	25	25	25	25	30	35	
CH	150	25	25	20	20	20	20	25	25	25	30	35	
	50	12	25	20	60	20	25	50	50	25	35	35	

Slides classified by treatment material, time period, and variables scored by the examiners.

TABLE 11. Pulpotomy

Material	Time (Days)	Inflammation (%)		Impact of Pulp-capping Agents (%)	Dentin Bridge Formation (%)		Dentin Chips (%)	Dentin Formation Quality (Tubules) (%)		Dentin Bridge Location (%)		Connective Tissue (%)	
		Slight or No Inflammation	Necrosis		Complete	Incomplete		Present	Absent	Pulp Exposure Interface	Other Locations	Present	Absent
MTA	150	45	10	40	50	50	60	20	100	75	25		
AEDB	50	45		40	50	50	40	40	25				
AEDB	150	12	37	13	25	25	40	50	25	25	25	75	25
AEDB	50	25	25	13	20	20	20	50	25	50	50	75	25
CH	150	40	40	40	20	20	60	34	100	50	50	50	50

Slides classified by treatment material, time period, and variables scored by the examiners.

TABLE 12. Pulp inflammation for the three treatment groups and the control (mean ± SD)

Material	Treatment	50 Days	150 Days
Ca(OH) ₂	Pulp capping	3.87 ± 1.93	4.37 ± 2.13
	Pulpotomy	4.25 ± 2.52	6.00 ± 0.00
AEDB	Pulp capping	5.00 ± 2.00	2.16 ± 0.29
	Pulpotomy	4.12 ± 2.39	3.50 ± 2.34
MTA	Pulp capping	1.50 ± 0.54	2.62 ± 2.25
	Pulpotomy	1.20 ± 0.23	2.80 ± 2.30
Control		1.00 ± 0.00	1.12 ± 0.25

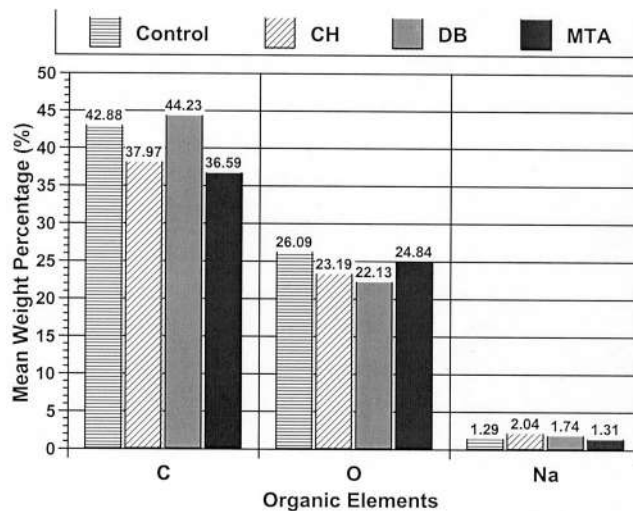


FIG 1. Pulp capping: mean weight percentages for organic elements found in the dentin bridge for the three treatment groups and the control group.

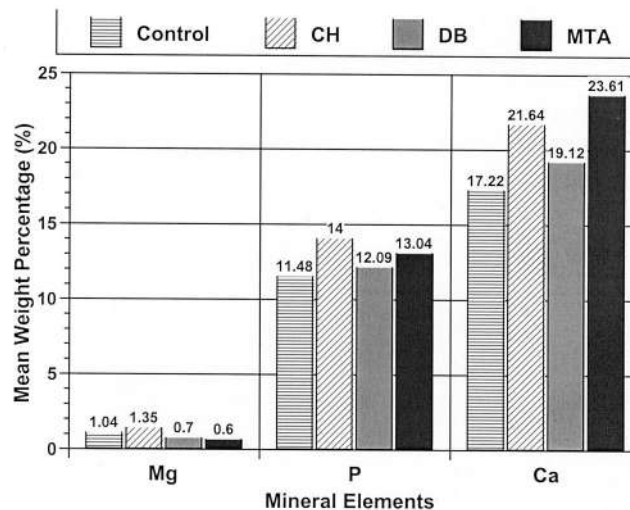


FIG 2. Pulp capping: mean weight percentages for mineral elements found in the dentin bridge for the three treatment groups and the control group.

- **Organic components:** MTA's mean weight percentage in carbon and sodium were closest to the control. For oxygen, AEDB's organic component was closest to the control, followed by MTA and CH.
- **Mineral components:** CH's concentration in magnesium was

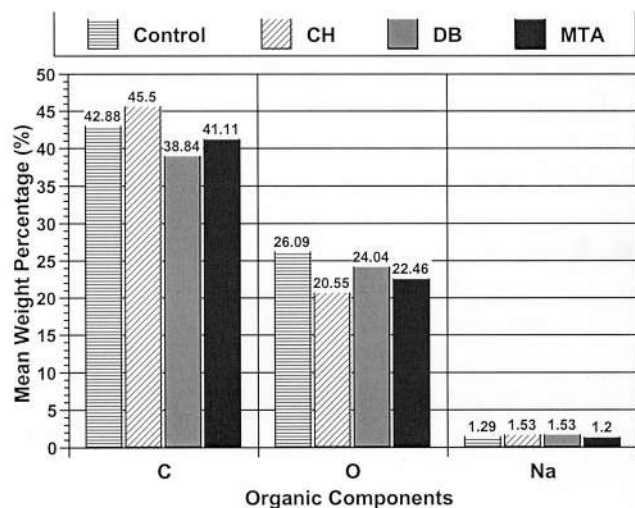


FIG 3. Pulpotomy: mean weight percentages for organic elements found in the dentin bridge for the three treatment groups and the control group.

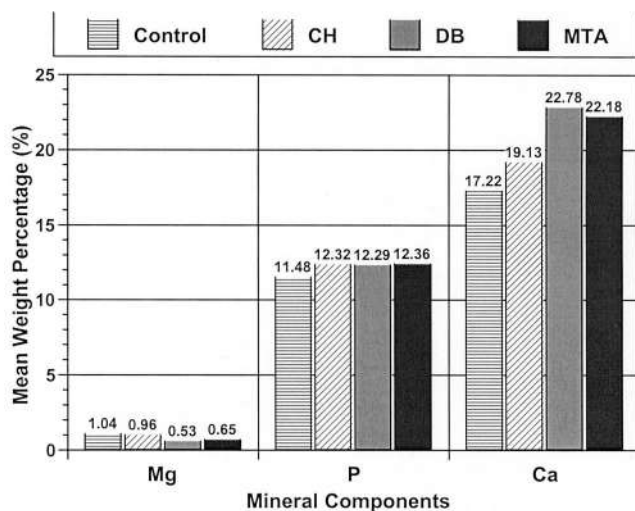


FIG 4. Pulpotomy: mean weight percentages for mineral elements found in the dentin bridge for the three treatment groups and the control group.

closer to the control's, although all mean percentages were below 1%. MTA's and AEDB's average weight percentages in calcium were higher than both CH's and the control's. For phosphorous, all three materials had virtually identical mean weight percentages and were less than 1% higher than the control.

DISCUSSION

Pulp Capping

The vital pulp-therapy procedures of pulp capping and pulpotomy are performed frequently by dentists, most likely on a weekly basis. Predominantly, these procedures are taught in dental school as a temporary treatment on cariously and mechanically exposed teeth. However, some authors (5, 13) have suggested that vital-

pulp therapy treatments can be permanent. Because the pulp has enough vital tissue, Stanley (5) advocated that pulp-capping procedures could be performed successfully on an asymptomatic carious exposure. Haskell et al. (13) supported this with a clinical study, which proved that asymptomatic carious exposures could survive an average of 12 yr after pulp capping. The development of newer materials that are biocompatible, bactericidal, inductive of a reparative process, and have better sealing properties could render these treatments long-term.

One of the newest materials that has appeared recently is MTA. MTA's properties are well established: (a) it has good sealing ability when compared to amalgam or Super-EBA, and it is not affected by blood contamination (14); (b) it is less cytotoxic than IRM or Super-EBA (9); and (c) it has a pH of 12.5 (9), which may imply the presence of bactericidal properties. In this dog study the results of MTA are promising when compared to CH and AEDB.

The results of pulp capping in this dog study show that MTA caused the least necrosis; only one of the cases in the 150-day group necrosed, whereas the majority had no or slight inflammation. AEDB and CH had a similar number of cases with necrosis in the 150-day group. There were almost twice as many cases of necrosis in the 50-day group for AEDB compared with CH, but as time progressed, the effect of these two materials became less distinguishable. In contrast, MTA was the only material whose effect on necrosis in the 150-day group was not statistically different when compared to the untreated tooth. Moreover, MTA was statistically closer to the control group ($p > 0.05$) regarding pulpal inflammation, in both the 50- and 150-day groups. In future work, it would be interesting to test whether MTA's physical and anti-bacterial properties change in timeframes beyond 5 months.

The impaction of pulp-capping agents into the pulp was not a discriminating factor among the three materials, because the findings were similar for the three treatment groups. Impaction of pulp-capping agents causes similar effects to that of dentin chips. The impaction of pulp-capping agents could be related to a combination of material composition and technique used. Preferably, the material should be placed carefully on the exposed pulp surface and not pressed into the pulp tissue. Deep impaction of the material can reduce the rate of healing and bridge formation. Also, as with dentin chips, the materials impacted could stimulate a healing response in the pulp.

Dentin chips were present in the MTA and CH groups, and this could be related to the type of bur and instrument used; although in this study the same technique was used in all the samples. Dentin chips may promote or retard healing (5). If they are confined to the superficial portions of the exposure, healing may be promoted (5). If the chips are numerous, and localized deeper into the pulp tissue, they may have a deleterious effect (5).

The concept of bridging is a controversial issue, because the presence of a bridge does not necessarily imply that the pulp tissue is healthy. Rather, it can be viewed as both a healing response and a reaction to irritation (15). Furthermore, the formation of a bridge does not imply that the pulp will be sealed completely from the environment. The bridges that are formed are initially permeable but as time progresses their permeability decreases (16).

A limitation of these studies in which serial sectioning was used is that it is not always possible to section perfectly on the perpendicular axis of the tooth. It is for this reason that many of the sections could not be scored for the presence of bridges. Consequently, the bridges could not be categorized as being present or absent. Nevertheless, they were scored with the additional criteria described in a previous section.

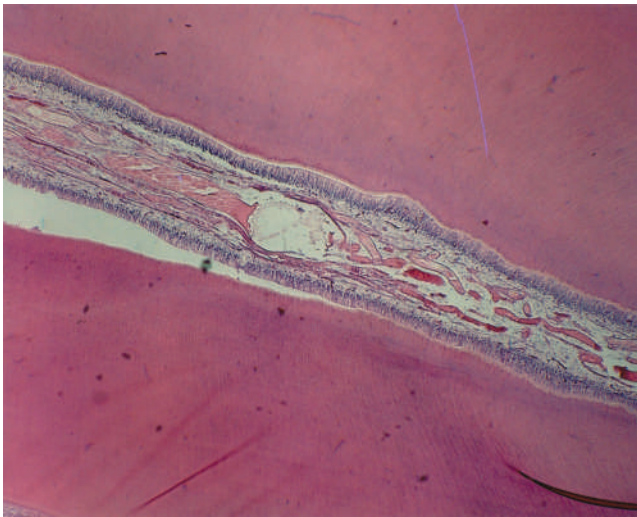


FIG 5. Untreated dog's tooth showing a normal pulp. (H&E: original magnification $\times 10$).

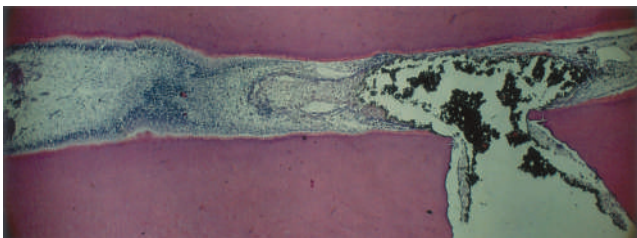

FIG 6. Pulp capping with MTA at 50 days showing impaction of the material in the pulp. No bridge formation is evident. Normal pulp underlines the material impaction. (H&E: original magnification $\times 10$).

In none of the slides for the AEDB group was bridging at the pulp-exposure interface observed. CH and MTA had bridge formation in equal proportions at the pulp-exposure interface and at other sites. AEDB did not have a complete bridge in any of the cases, compared with 30% of cases for MTA and 20% of cases for CH. The absence of complete bridging in the AEDB group corresponds to a higher initial degree of inflammation and the inability of the pulp to form reparative dentin. Although on some of the 50-day slides CH indicated complete bridge formation, the amount of necrosis was similar to AEDB's at 150 days. In contrast, MTA had more complete bridges formed regardless of timeframe (Figs. 5–7).

Reparative dentin was not present at the pulp-exposure interface when AEDB was used but was present when CH and MTA were applied. AEDB had new dentin formation at other pulpal sites, whereas tubule formation in the reparative dentin was more prevalent under AEDB. The reparative dentin did not originate from severely damaged odontoblasts; instead, the degenerated odontoblasts were replaced by undifferentiated cells that migrated from the deep regions of the pulp (17). This explains why the reparative dentin is regular when it is formed from areas where the odontoblasts remain intact. Most likely, this phenomenon was a reaction of the pulp to the pulp-capping agent applied. The presence or absence of connective tissue in the bridges was similar in all treatment groups, leading to the speculation that these bridges were not completely mineralized but also had some connective tissue component included in the bridges (detailed in the "Pulpotomy" section).

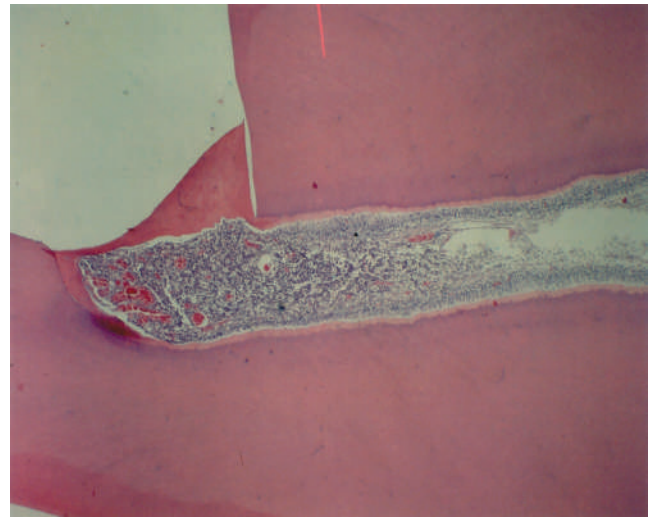


FIG 7. Pulp capping with Ca(OH)_2 at 50 days showing bridge formation and abscess under the bridge. (H&E: original magnification $\times 10$).

Because the present experiments did not extend beyond 150 days, it is unknown whether MTA's effect on pulp capping varies as a function of time. Furthermore, the pulp-capping procedures used here resulted in the pulp being mechanically exposed. In future work, pulp reaction to MTA in carious pulp exposures should be tested. It is for this reason that knowledge of the mechanism of action of MTA is important.

MTA's mechanism of action regarding hard-tissue formation seems to be similar to CH's (described in the "Scanning Electron Microscopy" section). The difference with CH lies in the presence of calcium oxide in MTA, which may explain the lack of initial necrosis in hard-tissue deposition that CH causes to the pulp tissue (18).

Pulpotomy

Pulpotomy is a different treatment modality from pulp capping. Pulpotomy is usually applied on a more temporary basis than pulp capping; a common example would be maintaining the radicular pulp tissue for apexogenesis in a recently erupted permanent tooth.

Similarly to pulp capping, pulpotomies reacted more favorably to use of MTA compared with CH or AEDB. Only one case in the 150-day group progressed to necrosis, as opposed to 67% of the cases that necrosed when treated with AEDB and 80% of the cases when treated with CH. Impaction of the pulp tissue was similar for the three materials used, so it is unlikely that this would be a differentiating factor for MTA, AEDB, and CH regarding tooth necrosis. Dentin chips in the pulp were observed on all slides, regardless of the material used. However, CH had a higher percentage of dentin chips (80%) compared with MTA (60%) and AEDB (60%). The pulpotomy technique will produce more dentin chip impaction compared with pulp capping because more pulp tissue is exposed.

The percentage of bridging was equal at the pulp-exposure interface and at other sites for AEDB (Fig. 8), which was most likely related to the initial inflammatory process by AEDB (more detailed explanation is given in the "Pulp-Capping" section). MTA and CH only had bridging present at the pulp-exposure interface

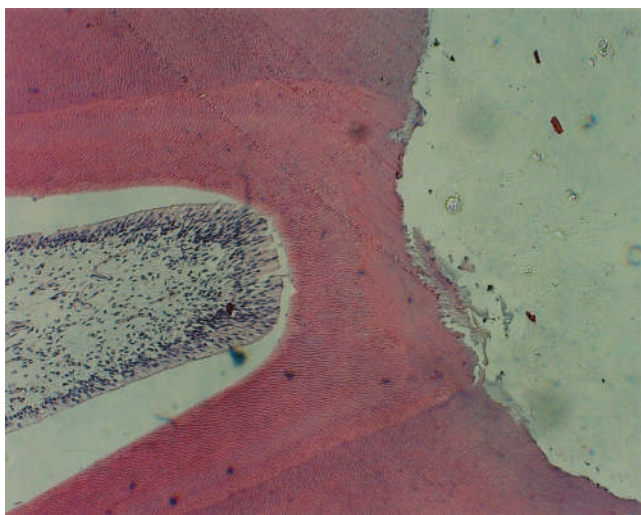


FIG 8. Pulpotomy with AEDB at 50 days showing bridge formation and healthy pulp under the bridge. (H&E; original magnification $\times 10$).

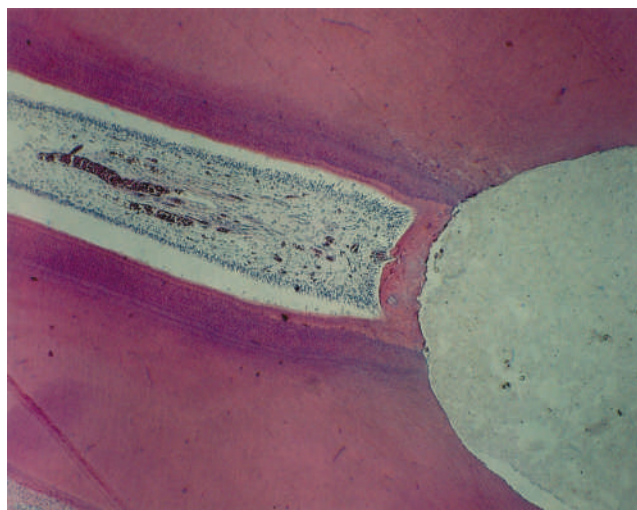


FIG 10. Pulpotomy with MTA at 50 days showing bridge formation and healthy pulp under the bridge. (H&E; original magnification $\times 10$).

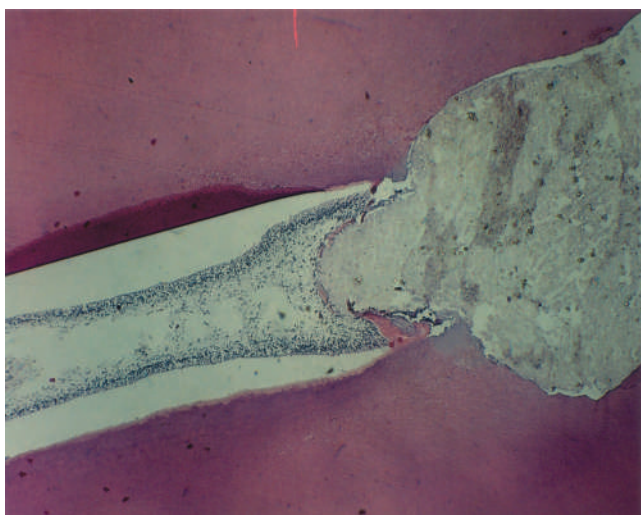


FIG 9. Pulpotomy with MTA at 50 days showing impactation of the material in the pulp. No bridge formation is evident. Healthy pulp tissue underlines the material impactation. (H&E; original magnification $\times 10$).

(Figs. 9 and 10). Tubule formation in the bridge was higher in the AEDB and CH cases than in the MTA cases. Conversely, CH had a lower percentage of complete bridging, whereas AEDB resulted in more complete bridges.

Connective tissue was present in all the bridges of the teeth treated with CH and in the majority of the bridges treated with MTA and AEDB. This could be explained by the fast initial disorganized formation of the reparative dentin that engulfs cellular inclusions. With time, this reparative dentin becomes more mineralized at the surface and more regular as the bridge matures and begins tubular dentin formation.

Scanning Electron Microscopy

EDXA was used to determine and measure the elements present in bridges formed at 150 days for each of the materials tested. Only

four bridges were present on the slides in each of the vital-pulp therapy treatment groups.

When compared to the control group, the percentages of the elements present were different between pulpotomy and pulp capping. This could be related to the higher degree of contact between the material and the pulp in pulpotomy procedures. Furthermore, in pulpotomy procedures, an amputation of the coronal pulp results in vascular changes in the pulp. Kishi et al. (19) described these changes as follows: "with the subsequent formation of a concave region due to the compression of the material placed against the pulp, a flat, dense capillary network develops around this concave region. Two weeks after the pulpotomy, the concave region becomes shallower and a flat capillary network is distributed around the region floor, at which time a few bridges can be seen. Four weeks after pulpotomy, the thickness of the bridge increases and a dense capillary network is formed underneath. Eight weeks after pulpotomy, the vascular network beneath the bridge shows similar features as in the three layers of the normal pulpal network." These capillary changes could explain the difference in the mineral content between the bridges formed in pulpotomy and pulp-capping.

In pulp-capping procedures, the organic component in the cases treated with CH and MTA was closest in value to the control group. Conversely, cases treated with AEDB had a higher cellular component. Based on this study's histological analysis, AEDB had a higher degree of inflammation compared with MTA. Furthermore, AEDB did not exhibit any complete bridging or any bridging at the pulp-exposure interface.

MTA's oxygen and sodium weight percentages were closest to the control group compared with the other materials. Also, because MTA had the highest oxygen component, a deleterious environment for the anaerobic bacteria may exist. With regards to the calcified component of the bridge in pulp capping, AEDB was closest to the control for calcium and phosphorous concentrations. However, MTA and CH formed bridges with a higher calcified component than AEDB. This indicates that the bridging might be less permeable than normal dentin, which may translate into better isolation of the pulp from the oral environment.

MTA and CH seem to have a similar mechanism of action that encourages hard-tissue deposition. CH has been described (20) as

having a direct effect on the precapillary sphincters, thus resulting in less plasma outflow, which, in turn, favors a calcific response in the involved tissue. CH also increases the action of pyrophosphatase, which is calcium-ion dependent; this enzyme transforms pyrophosphate to orthophosphate, which increases energy utilization and, therefore, favors defense and repair mechanisms. Holland et al. (18) has suggested that this hard-tissue deposition could be due to the calcium oxide present in MTA, which may have a similar mechanism of action to CH. MTA had the lowest value for magnesium, followed by AEDB and CH. The role of the minute element weight percentage of magnesium in the dentin bridge is still unknown. It is speculated that it slows the mineralization process. The relative Mg:Ca ratio stabilizes both the amorphous calcium phosphate deposition and the formation of poorly crystallized hydroxyapatite.

In pulpotomy procedures, MTA resulted in organic concentrations of carbon and sodium that were closer to the control. Conversely, AEDB had a higher oxygen component than MTA and CH, making AEDB a more aerobic environment than MTA or CH. With regard to the calcified component of the bridge, CH was closer to the control for the entire set of mineral components, followed closely by MTA and less so by AEDB. CH, therefore, creates a bridge that is probably similar to normal dentin. Histological assessment indicated that MTA's properties did not appear to be affected by time, at least not within the 150-day time period studied. Thus, compared with CH, MTA may have superior sealability properties and be less cytotoxic to the tissues.

On a comparative basis, MTA gave the best pulpal responses to pulp capping and pulpotomy. MTA had fewer cases of pulpal necrosis, with none of the cases showing necrosis in the short-term and only 10% of the cases being necrosed in the long-term. In pulp capping cases, MTA was superior to CH and AEDB regardless of time. In pulpotomy procedures, MTA, AEDB, and CH performed similarly in the short-term, whereas MTA was significantly better in the long-term. Finally, MTA gave a more predictable, positive response in vital pulp therapy than CH and AEDB at longer timeframes.

This project was partially funded by a research grant from Dentsply Tulsa Dental, Tulsa, OK.

The authors thank Ms. Jo Taylor for help with tissue processing and slide preparation.

Drs. Dominguez, Witherspoon, and Gutmann are affiliated with the Department of Restorative Sciences, Graduate Endodontics, and Dr. Opperman is affiliated with the Department of Biomedical Sciences and Center for

Craniofacial Research and Diagnosis, Baylor College of Dentistry, A Member of the Texas A&M University Health Science Center, Dallas, TX. Address requests for reprints to Dr. James L. Gutmann, Department of Restorative Sciences, TAMUS-HSC-Baylor College of Dentistry, 3302 Gaston Ave., Dallas, TX 75246.

References

1. Grossman LI. Root canal therapy. 4th ed. Philadelphia: Lea & Febiger, 1955.
2. Schroder U. Evaluation of healing following experimental pulpotomy of intact human teeth and capping with calcium hydroxide. *Odontol Revy* 1972; 23:329-40.
3. Fisher FJ, McCabe JF. Calcium hydroxide base materials. An investigation into the relationship between chemical structure and antibacterial properties. *Br Dent J* 1978;144:341-4.
4. Stanley HR. Criteria for standardizing and increasing credibility of direct pulp-capping studies. *Am J Dent* 1998;11 Spec No:S17-34.
5. Stanley HR. Pulp capping: conserving the dental pulp—can it be done? Is it worth it? *Oral Surg Oral Med Oral Pathol* 1989;68:628-39.
6. Snuggs HM, Cox CF, Powell CS, White KC. Pulpal healing and dentinal bridge formation in an acidic environment. *Quintessence Int* 1993;24:501-10.
7. Pameijer CH, Stanley HR. The disastrous effects of the "total etch" technique in vital pulp capping in primates [published erratum appears in *Am J Dent* 1998;11:148]. *Am J Dent* 1998;11 Spec No:S45-54.
8. Gwinnett AJ, Tay F. Early and intermediate time response of the dental pulp to an acid etch technique in vivo. *Am J Dent* 1998;11 Spec No:S35-44.
9. Torabinejad M, Hong CU, McDonald F, Pitt Ford TR. Physical and chemical properties of a new root-end filling material. *J Endodon* 1995;21: 349-53.
10. Torabinejad M, Pitt Ford TR. Root end filling materials: a review. *Endod Dent Traumatol* 1996;12:161-78.
11. Abedi H, Torabinejad M, Pitt Ford TR, Backland LK. The use of mineral trioxide aggregate cement (MTA) as a direct pulp-capping agent. *J Endodon* 1996;22:199.
12. Pitt Ford TR, Torabinejad M, Abedi HR, Backland LF. Using mineral trioxide aggregate as a pulp-capping material. *J Am Dent Assoc* 1996;127: 1491-4.
13. Haskell EW, Stanley HR, Chellemi J, Stringfellow H. Direct pulp capping treatment: a long-term follow-up. *J Am Dent Assoc* 1978;97:607-12.
14. Torabinejad M, Higa RK, McKendry DJ, Pitt Ford TR. Dye leakage of four root end filling materials: effects of blood contamination. *J Endodon* 1994;20:159-63.
15. Schroder U. Effects of calcium hydroxide-containing pulp-capping agents on pulp cell migration, proliferation, and differentiation. *J Dent Res* 1985;64:541-8.
16. Franz FE, Holz J, Baume LJ. Microradiographic assessment of neodontal bridging following direct pulp capping in human teeth. *J Endodon* 1985;11:6-10.
17. Veis A. The role of dental pulp—thoughts on the session on pulp repair processes. *J Dent Res* 1985;64 Spec No:552-4.
18. Holland R, de Souza V, Nery MJ, Otoboni Filho JA, Bernabe PF, Dezan Junior E. Reaction of rat connective tissue to implanted dentin tubes filled with mineral trioxide aggregate or calcium hydroxide. *J Endodon* 1999;25:161-6.
19. Kishi Y, Shimozato N, Takahashi K. Vascularization after pulpotomy. *Proc Finn Dent Soc* 1992;88:487-90.
20. Heithersay GS. Calcium hydroxide in the treatment of pulpless teeth with associated pathology. *J Br Endod Soc* 1975;8:74-93.